

# In depth proteomics of the kidneys from autoimmune type I diabetes rat model through MALDI - Imaging Mass Spectrometry

## Introduction

Diabetic nephropathy (DN) is one of the serious chronic complications of type 1 diabetes (T1D). Although microalbuminuria has been used as a primary marker of DN in early stage, it is sometimes difficult to make an early diagnosis of DN simply relied on the current criteria. Unraveling pathogenesis of DN and finding additional early markers of DN is extremely important.

Microvascular lesions in the renal glomeruli is a typical hallmark of the DN. Aberrant homeostasis in blood glucose tolerance may cause systemic damages to vascular systems including glomerulus and arteriole. In addition, several lines of evidence show hyperglycemia is not a single factor of diabetes - induced microvascular complication.

Here we adopt matrix-assisted laser desorption/ionization (MALDI) mass imaging mass spectrometry (IMS) approach to study early proteomic tissue marker of the kidneys from KDP rat, which has been well established T1DM model in comparison with KND rat as normal control.

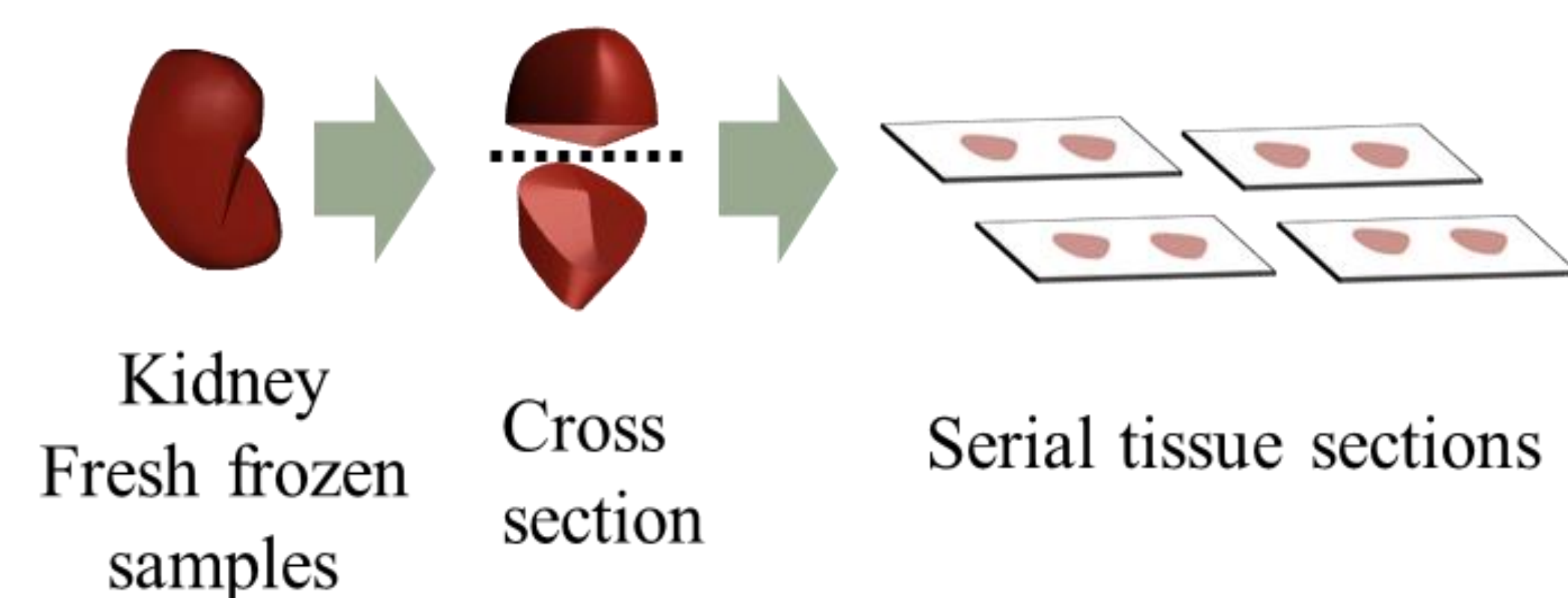
## Methods

### ►Histopathological examination in the kidney

Kidneys from KDP rats at 7 weeks of age were resected and snap-frozen in liquid nitrogen. Normal KND rat kidneys were obtained at 7 weeks of age as control. Sacrifice time was not identical.

### ►Animals

Fresh frozen kidneys from KND and KDP rats were cut into 6  $\mu\text{m}$  to 10  $\mu\text{m}$  sections. The sections were mounted on glass slides and subjected to standard Hematoxylin-Eosin (HE) staining, Periodic acid-Schiff (PAS) staining and Immunohistochemistry (IHC).



### ►MALDI-IMS

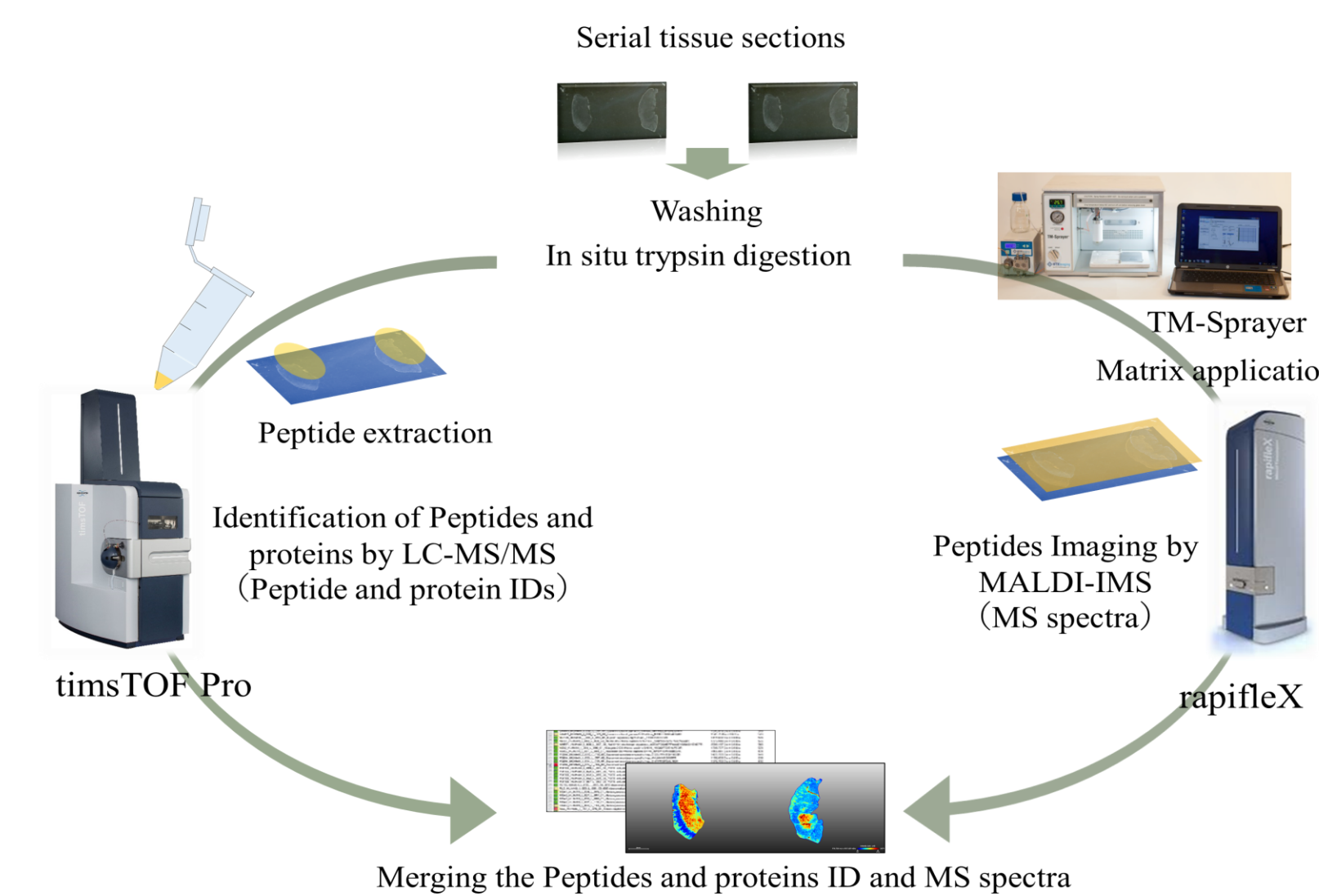
10  $\mu\text{m}$  cryosections were cut and transferred to Indium-Tin-Oxide (ITO) coated glass slides. Trypsin and  $\alpha$ -Cyano-4-hydroxycinnamic acid (HCCA) was uniformly deposited on the slide using the TM-Sprayer™ (HTX Imaging) device and measured using rapifleX tissue typer (Bruker Daltonik GmbH) with a spatial resolution of 50  $\mu\text{m}$  in linear mode. Ions were detected in a mass range of  $m/z$  800 to 3000.

### ►LC-MS/MS

For the serial section of the tissues exactly prepared with the same protocol for MALDI-IMS, proteins and peptides were extracted to be analyzed with timsTOF Pro (Bruker Daltonik GmbH) with nanoElute (Bruker Daltonik GmbH).

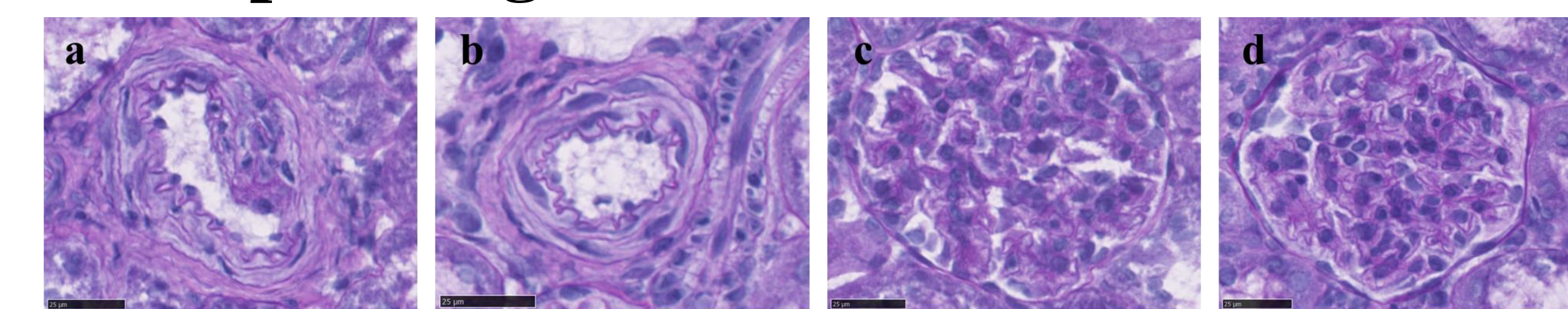
### ►Data analysis

Obtained mass spectra from MALDI-IMS were visualized with flexImaging (Bruker Daltonik GmbH) and SCiLS Lab 2020 software (Bruker Daltonik GmbH). Obtained mass spectra from LC-MS/MS were identified peptides and proteins in the tissue with ProteinScape (Bruker Daltonik GmbH). By Image ID analysis to integrate these data visualized peptides and proteins in the tissue.



## Results and Discussion

### ►Histopathological examination

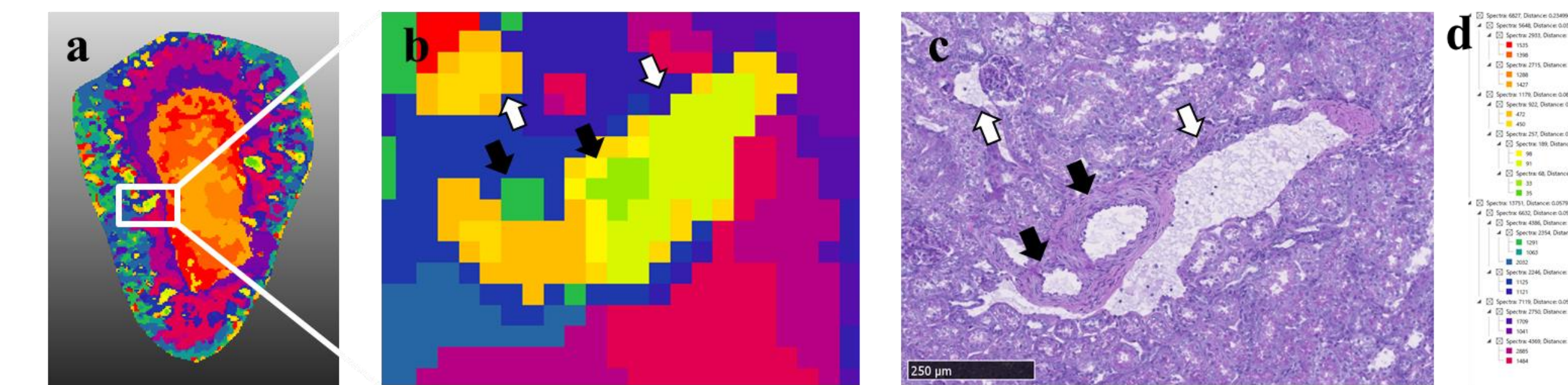


**Figure. 1 a-b:** PAS staining of the renal arteriole from KND rat and KDP rat at 7 weeks of age. **c-d:** PAS staining of the renal glomerulus from KND rat and KDP rat at 7 weeks of age. There are no pathological changes of renal arteriole and renal glomerulus. **a:** Renal arteriole from KND rat. **b:** Renal arteriole from KDP rat. **c:** Renal glomerulus from KND rat. **d:** Renal glomerulus from KDP rat. Bars=25  $\mu\text{m}$ .

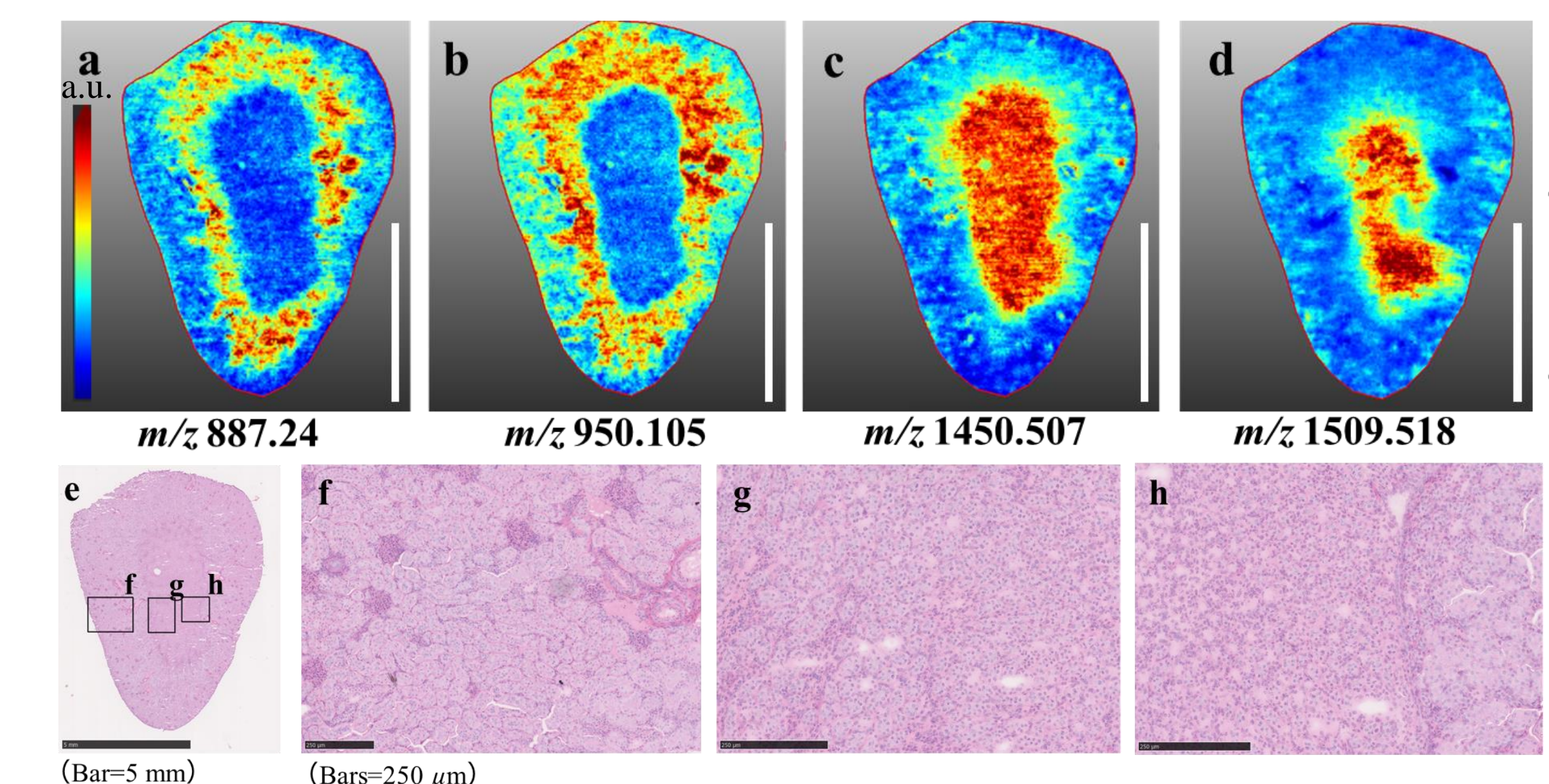
Konomi Uchida<sup>1</sup>, Yume Mukasa<sup>1</sup>, Kazuhiko Ishibashi<sup>2</sup>, Yuki Kuzuhara<sup>1</sup>, Takashi Nirasawa<sup>3</sup>, Ryo Kajita<sup>3</sup>, Hiroyuki Yanagi<sup>2</sup>, Nobuto Kakuda<sup>1</sup>, Masaya Ikegawa<sup>1</sup>

1. Faculty of Life and Medical Systems, Doshisha University, Kyotanabe, Kyoto, Japan 2. ONO pharmaceutical Co., Ltd, Fukui, Japan  
3. Bruker Japan K.K, Yokohama, Japan

### ►MALDI-IMS



**Figure. 2 a:** Proteomic segmentation map of kidney from KND rat at 7 weeks of age. Proteomic segmentations were clearly demarcated renal structures. Especially renal vascular was visualized clearly separated to renal artery ( $\rightarrow$ ) and renal vein ( $\Rightarrow$ ). **b:** Enlarged picture of renal vascular from Segmentation map. **c:** PAS staining of renal vascular. Bar = 250  $\mu\text{m}$ . **d:** Bisecting k-means based clustering analysis identified renal structures. The clusters and substructures and their relation was shown as nodes, e.g. 1-0-0.



**Figure. 3 a-d:** Single mass distribution of the kidney from KND rat at 7 weeks of age. Each single mass represents renal structure, **a:** inner cortex, **b:** Inner and a part of the outer cortex, **c:** papilla and medulla, **d:** medulla. Bars=5 mm. **e-h:** HE staining after measuring of the kidney from KND rat. **e:** Whole kidney tissue of KND rat at 7 weeks of age. Bar=5 mm. **f:** Renal cortex, **g:** Renal medulla, **h:** Renal papilla and pelvis. Bars=250  $\mu\text{m}$ .

## Summary

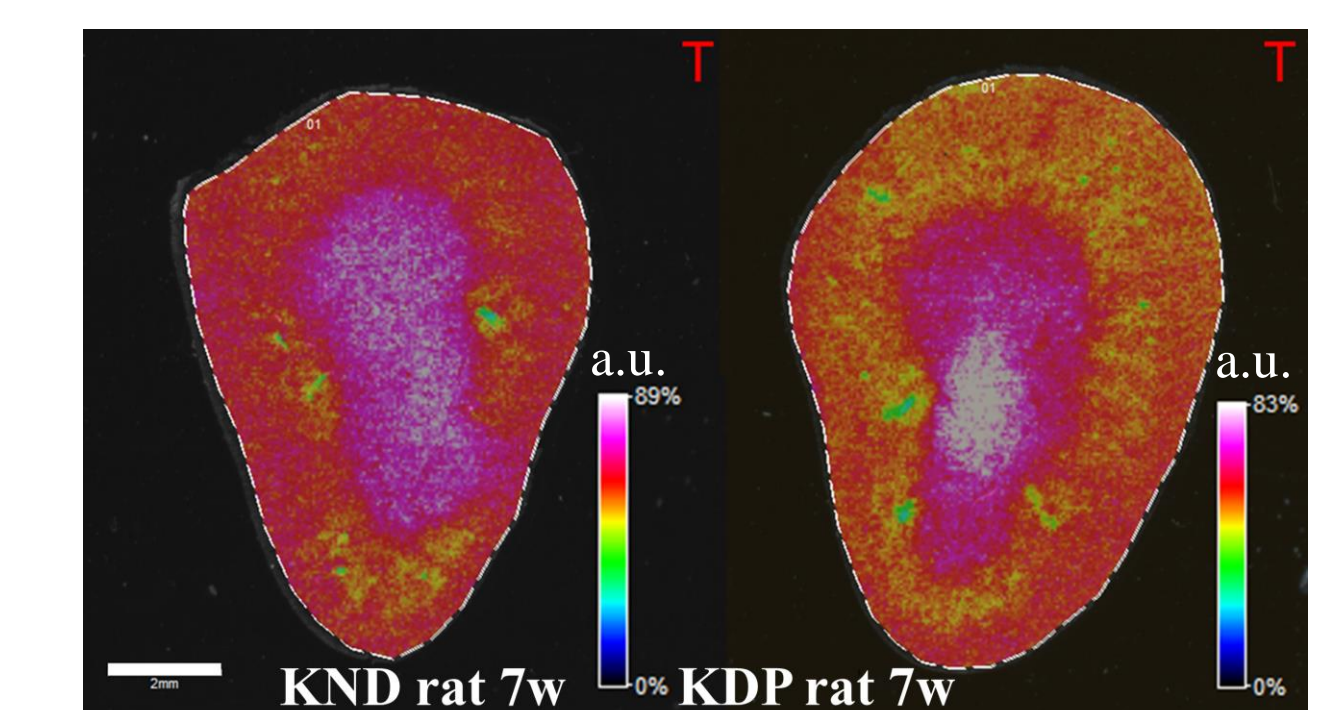
- Kidneys from T1D animal model, KDP rat at 7 weeks of age were successfully applied to MALDI-IMS and a shotgun proteomics.
- We have identified both morphological and functional proteins from kidneys of KDP and KND rat at 7 weeks of age through shotgun proteomics.
- By Protein ID analysis, we have succeeded in visualization of the identified proteins, such as Moesin with MALDI-IMS, which can be a traceable marker for DN development in the future study.

### ►LC-MS/MS

Alpha-1-macroglobulin
Ceruloplasmin
Fibronectin
Clusterin
Apolipoprotein A-IV
Calmodulin-1
Complement component 1 Q subcomponent-binding protein, mitochondrial
Ferritin heavy chain
Transthyretin
Vimentin
Moesin

**Table. 1** List of proteins identified with LC-MS/MS. These proteins are specifically identified with DN and were detected high score by our measuring. The text with a gray background are known biomarkers and the others are Uncharacterized candidate marker proteins.

### ►Image ID analysis



**Figure. 4** Single mass distribution of the kidney from KND rat and KDP rat at 7 weeks of age. This spectrum shows peptide fragment of Moesin (1570.76 Da). Bar = 2 mm. Moesin belongs to ERM protein family and is related to renal function as well as renal diseases. In our IMS data for Moesin in early DN was identified at high score at all (n=5).

## References

- 1, Yokoi N. et al., (1997) *J Clin Invest.* 100(8):2015-2021.
- 2, Komeda K. et al., (1998) *Endocr. J.* 45(6):737-744.
- 3, Kawaguchi, K. et al., (2018) *Pflugers Arch.* 470(7):1055-1068.
- 4, Thongboonkerd, V. et al., (2004) *J Am Soc Nephrol.* 15(3):650-62.
- 5, Cristina, G. et al., (2016) *J Diabetes Res.* 2016:4626125.