

Unraveling pathogenesis of dilated cardiomyopathy (DCM) on J2N-k Hamster model using MALDI-Imaging Mass Spectrometry in combination with shotgun proteomics

Inori Shintani¹; Takashi Tsuji²; Mizuki Ishida¹; Takashi Nirasawa³; Ryo Kajita³; Hatsue Ishibashi-Ueda⁴; Hidetoshi Masumoto²; Kenji Minatoya²; Masaya Ikegawa¹

1. Doshisha University, Kyotanabe City, Japan; 2. Kyoto University, Kyoto, Japan;

3. Bruker Japan K. K., Yokohama, Japan; 4. National Cerebral and Cardiovascular Center Research Institute, Suita, Japan

Keywords

Proteomics, MALDI imaging, Biomarkers, shotgun proteomics, Dilated Cardiomyopathy (DCM), J2N-k Hamster model, heart

Introduction

Dilated Cardiomyopathy (DCM), a group of disorders characterized by cardiac dilation and reduced left ventricular ejection fraction, has an extremely poor prognosis. To investigate the pathogenesis of DCM, we performed global proteomic analysis of myocardial tissues from J2N-k cardiomyopathic hamsters. This model exhibits symptoms similar to those of human DCM, owing to the deletion of the δ -sarcoglycan gene and J2N-n hamsters are also available as a non - cardiomyopathic control. In the current study, we have combined in situ proteomics for cardiac tissues from hamsters by integrating Matrix - assisted laser desorption/ionization imaging mass spectrometry (MALDI IMS) and trapped ion mobility spectrometry (TIMS) TOF Pro instrument, which implements online parallel accumulation - serial fragmentation (PASEF) mode.

Methods

Animals; J2N-k and J2N-n hamsters at 4- to 13-weeks of age were sacrificed to obtain heart tissues which were snap-frozen in liquid nitrogen.

Sample preparation; 10 μ m frozen sections of hearts were cut on a cryostat and transferred to conductive Indium-Tin-Oxide (ITO) coated glass slides (Fig. 1).

MALDI-IMS (no digestion); Sinapic Acid (SA) 10 mg/ml in 50% Acetonitrile was uniformly deposited on the slide by using TM-Sprayer (HTX Imaging). Then extracted peptides and proteins are measured by using rapifleX (Bruker Daltonik GmbH) with a spatial resolution of 50 μ m. Ions were detected in mass range of m/z 2,000-20,000.

MALDI-IMS with shotgun proteomics (Fig. 2); α -cyano-4-hydroxycinnamic acid (CHCA) 10 mg/ml in 70% Acetonitrile was uniformly deposited on the slide by using TM-Sprayer. Then extracted peptides and proteins are measured by using rapifleX with a spatial resolution of 50 μ m. Ions were detected in mass range of m/z 800-4,000. On-tissue digestion with trypsin was performed with TM-Sprayer. By using tims TOF Pro with nanoElute (Bruker Daltonik GmbH), shotgun proteomics was performed with the same tissue sample. Column used was 25 cm \times 75 μ m, C18 column.

Data Analysis; Obtained mass spectra as well as annotated proteins and peptides were visualized with flexAnalysis, flexImaging5.0 and SCiLS Lab 2018b/2019b software (Bruker Daltonik GmbH). About 2,000 proteins were successfully annotated with ProteinScape4.0 (Bruker Daltonik GmbH), and database was Swiss-prot.

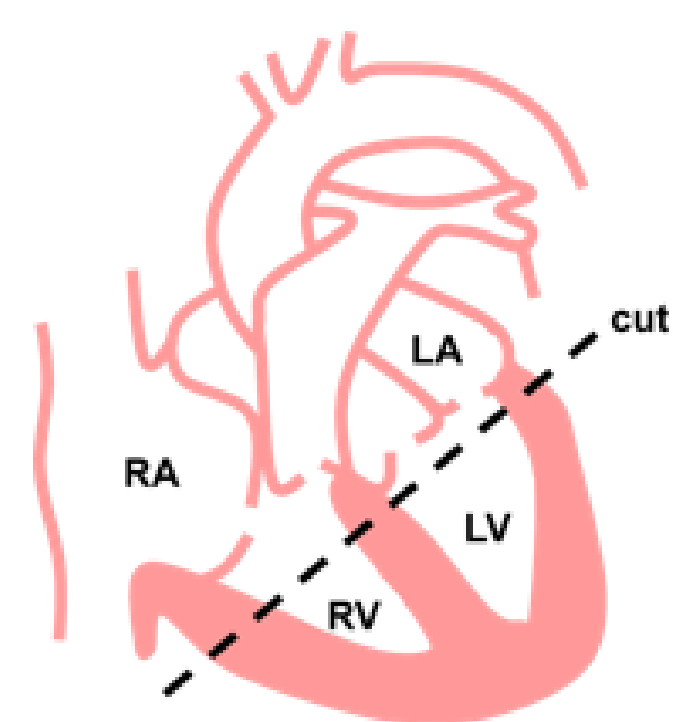


Fig. 1 Methods of getting axial sections
RA; Right atrium
LA; Left atrium
RV; Right ventricle
LV; Left ventricle

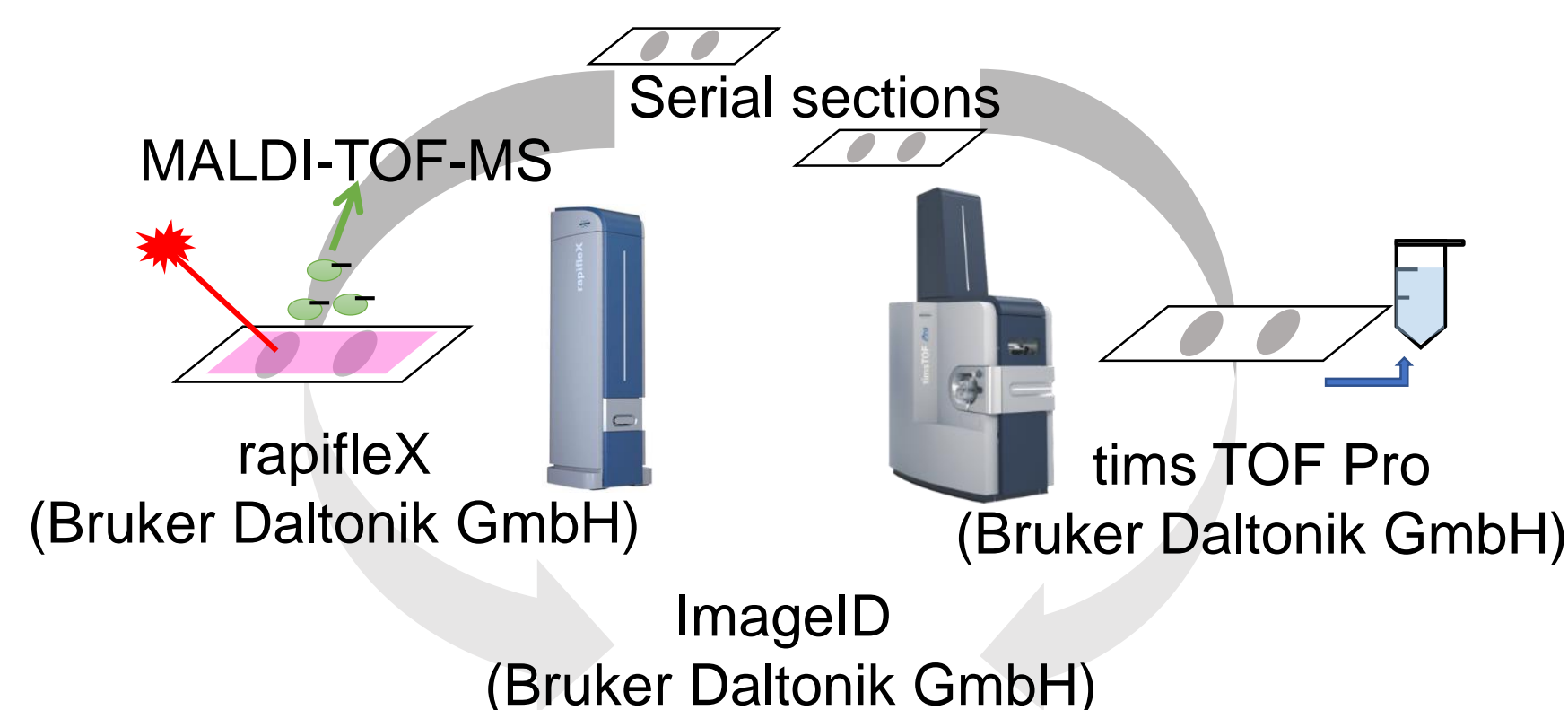


Fig. 2 Workflow image of combined analytical method

Histological Analysis

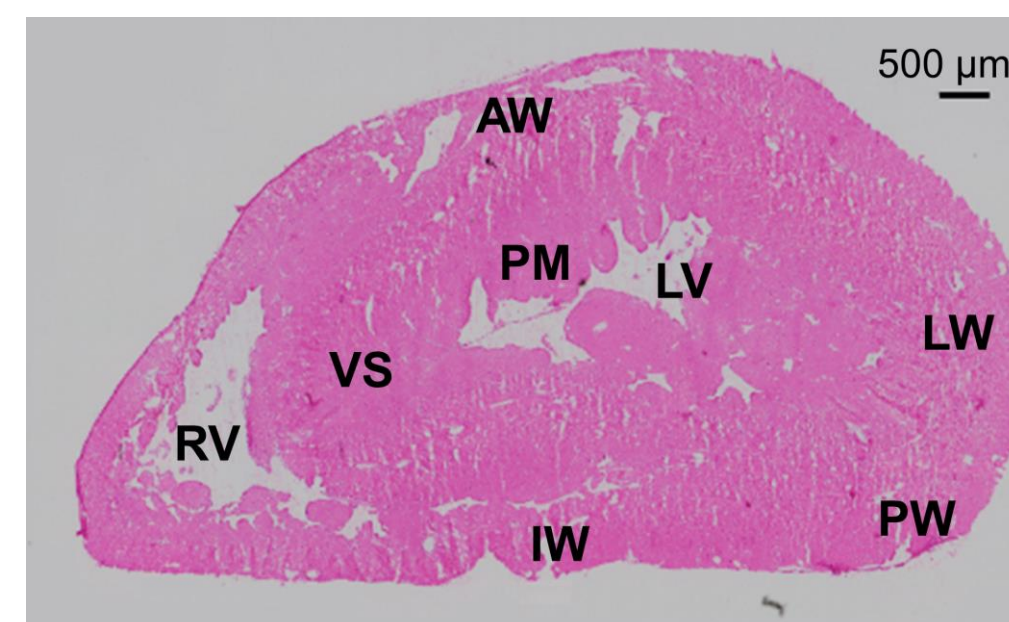


Fig.7 Histology of the Heart
RV; Right ventricle, LV; Left ventricle
VS; Ventricular septum, PM; Papillary muscle
AW; Anterior wall, PW; Posterior wall
IW; Inferior wall, LW; Lateral wall

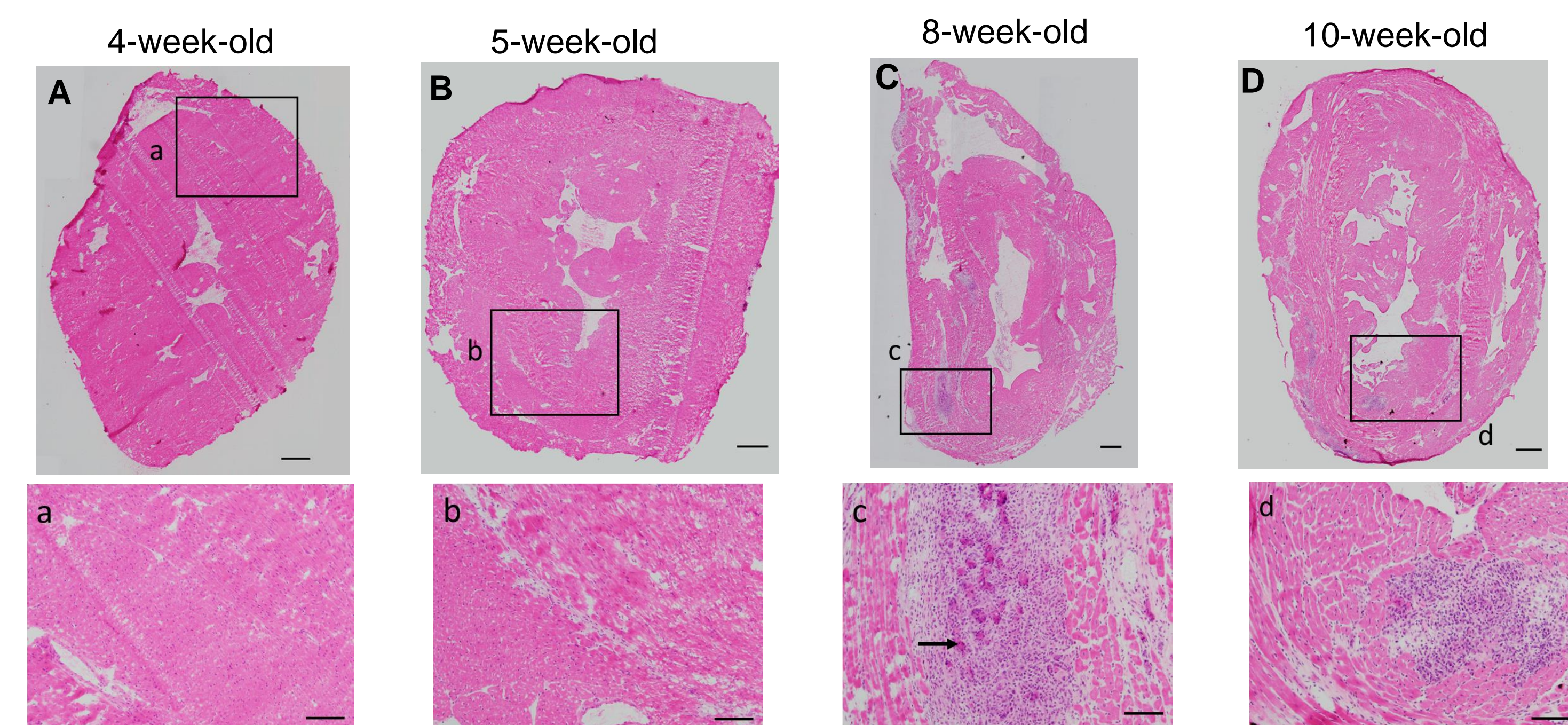


Fig. 8 Histological examination of J2N-k hamster with Hematoxylin and Eosin staining. A - D; bar = 500 μ m. a - d; bar = 100 μ m.
A; No change of myocytes and no cell infiltrations at ventricles.
B and b; Focal cell infiltrations.
C; Inflammatory infiltrations area was diffuse, and myocardial necrosis or degenerations were progressive.
c; Multinucleated giant cell (arrow).
D; Inflammatory infiltrations were decreased and they were identified not focal but diffuse.

Results

① The Analysis of native proteins by MALDI-IMS (no digestion)

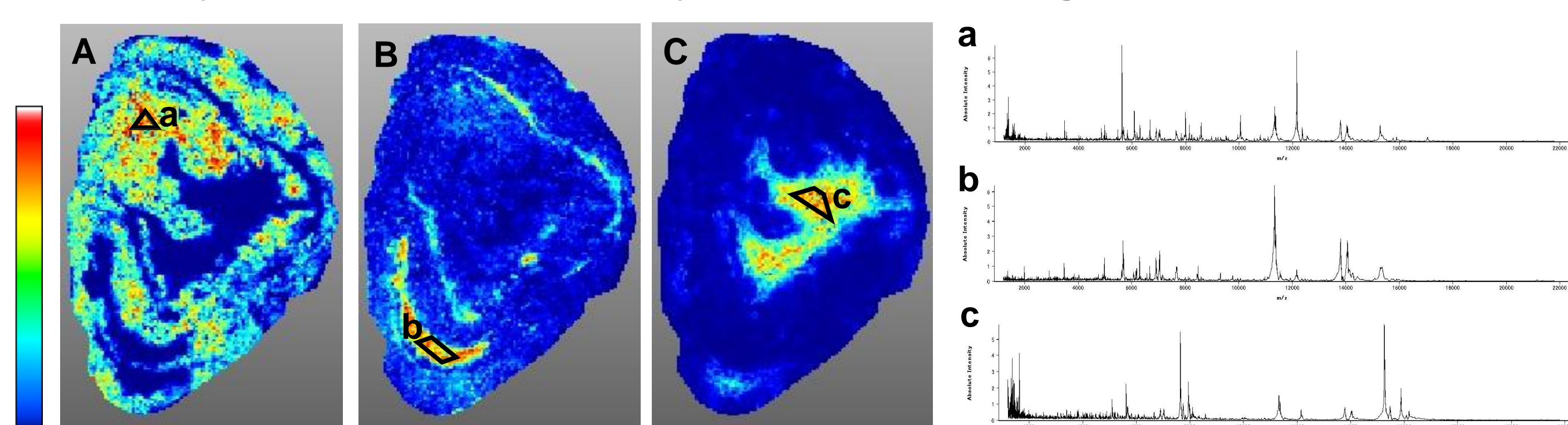


Fig. 3 Typical images of native proteins from J2N-k hamster (8wk) hearts by pLSA.
A; Non pathological myocyte area, B; Inflammatory region, C; Heart chamber
a - c; Mean spectrum of ROI in A-C

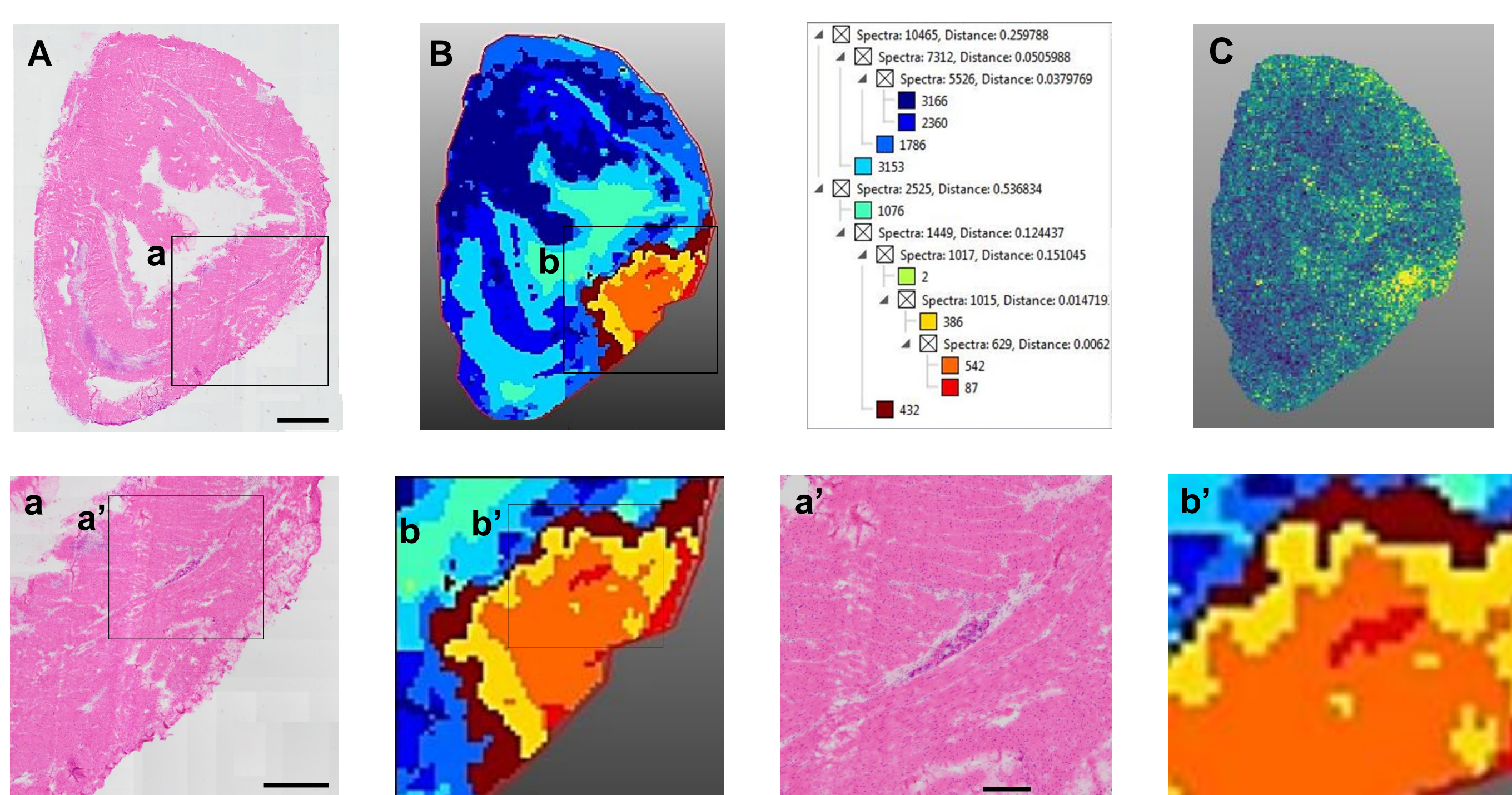


Fig. 4 *In-situ* proteome by segmentation analysis
A, a, a'; HE stain of 8-week-old J2N-k heart after IMS (bars; A = 1 mm, a = 2 mm, a' = 200 μ m)
B, b, b'; Segmentation map (SCiLS Lab 2018b.)
C; Single peak image (SCiLS Lab 2019b.)

② MALDI-IMS with shotgun proteomics (digestion)

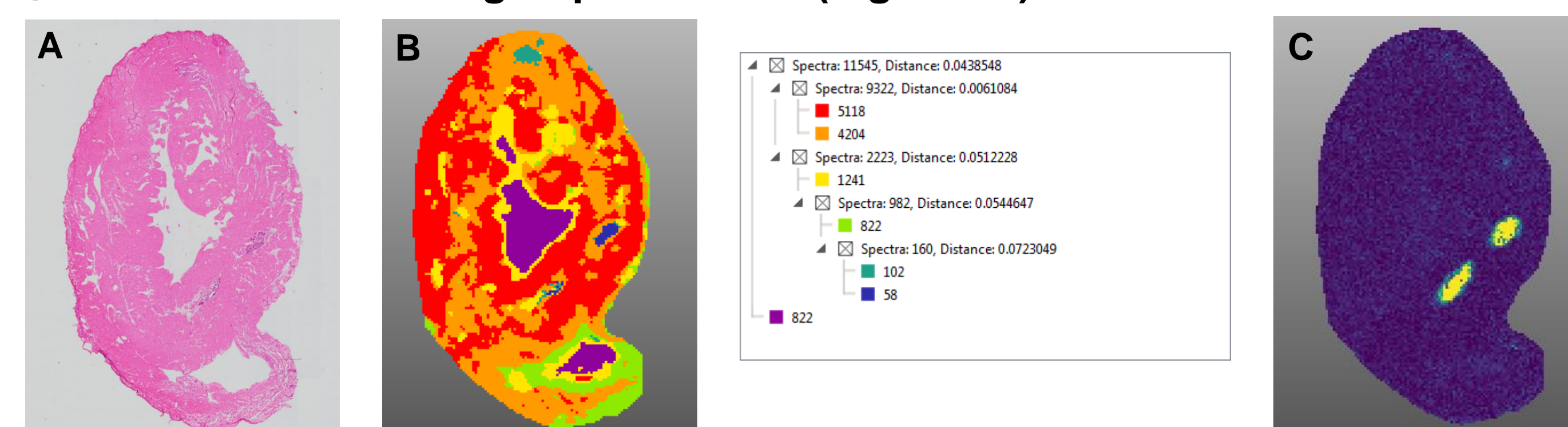


Fig. 5 *In-situ* proteome with on-tissue digestion by segmentation analysis
A; HE stain of 8-week-old J2N-k heart after IMS (bar = 500 μ m)
B; Segmentation map, C; Single peak image (SCiLS Lab 2019b.)

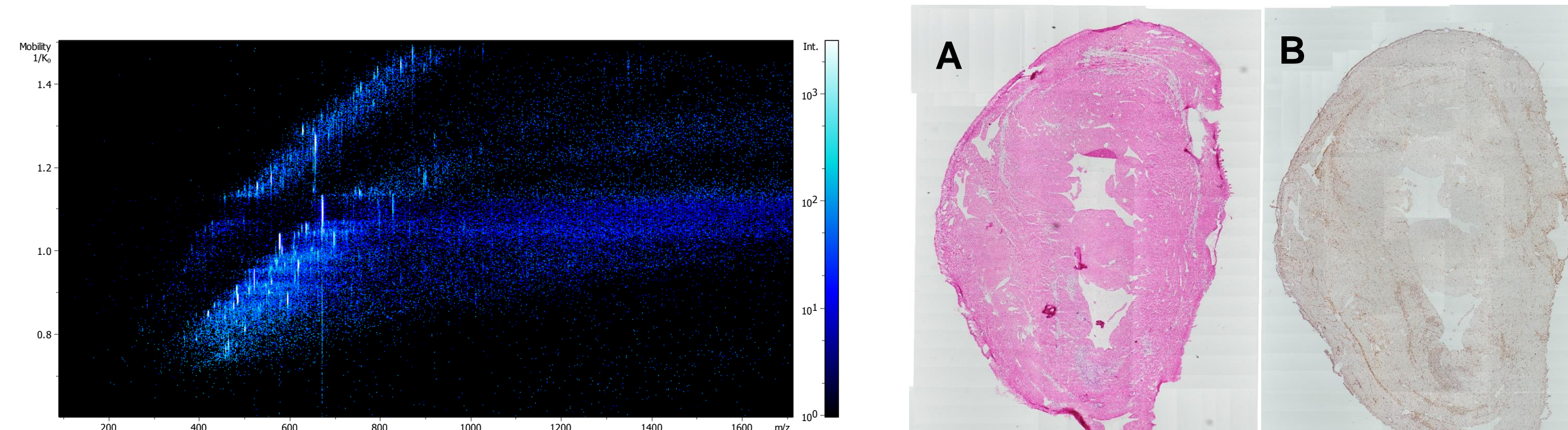
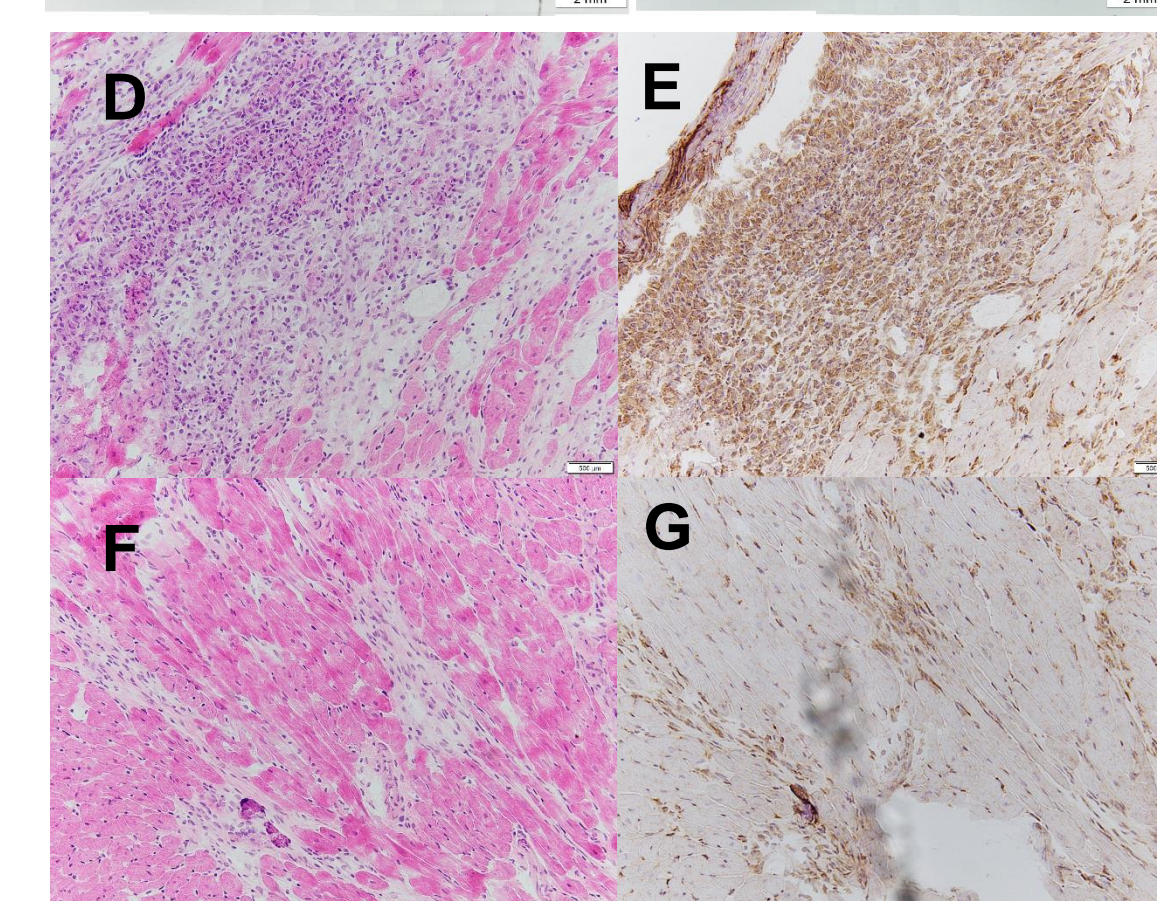


Fig. 6 Heatmap of 8-week-old J2N-k heart by Shotgun proteomics About 2,000 proteins were identified.

③ Immunohistochemistry

Fig. 7 A; HE staining of J2N-k heart. B. Immunohistochemistry (bar = 2.5 mm) for the protein A. D and F; enlarged view from A. E and G; enlarged view from B. This protein, annotated and was validated its specific localization to cell infiltration.



Conclusions

- We have established protocol of MALDI-IMS for heart tissues of J2N-k and J2N-n hamsters at proteomic level.
- We have succeeded in obtaining proteomic profiles of J2N-k hearts, well reflecting histological features such as inflammatory cell infiltrations.

- Proteins specific to the lesion of J2N-k hearts through an integrated protocol of MALDI-IMS and shotgun proteomics.